

Figure 2. Hippocampal NAA concentrations (A) and Cho:Cr peak intensities in the occipital cortex (B) plotted for severely fatigued and non-fatigued cancer survivors.

404

Reproducibility and variance of short echo time 1H MR chemical shift imaging of the human brain at 3T with automated planning software

S. Van Cauter[1], D. Sima[2], L. ter Beek[1], J. Luts[3], R. Li[3], M. Osorio Garcia[3], S. Sunaert[1], S. Van Huffel[3], U. Himmelreich[4];
[1]Radiology, University Hospitals Leuven, Leuven, Belgium, [2]Department of Electrical Engineering, Catholic University Leuven, Heverlee, Belgium, [3]Department of Electrical Engineering, Catholic University Leuven, Leuven, Belgium, [4]Medical Diagnostic Sciences - Molecular Small Animal Imaging Center, Catholic University Leuven, Leuven, Belgium.

Objectives: To validate the reproducibility and data quality of a rapid short echo time 2D CSI acquisition protocol (SENSE-CSI) and to investigate the role of automated repositioning software[1].
Methods: Ten healthy volunteers were imaged 3 times on 2 different 3T MR scanners. Each CSI measurement was immediately repeated without repositioning. In total, 120 CSI datasets were acquired. A T2-weighted image was acquired, using automated repositioning software with FOV alignment along the anterior and posterior commissure (AC-PC) on a scout image. The CSI grid was manually positioned at two slices above the ventricles. The CSI protocol had following imaging parameters: 2D PRESS, TE/TR: 35/2000ms, SENSE factor: LR: 2 AP: 1.8, acquisition time: 3min 30sec. Offset parameters of the CSI plane were analyzed at different time points within each volunteer. After preprocessing, quantification of NAA, Glu, Cre, PCh, GPCh, Gln, Lac, Ala, Myo, Tau and Lips was performed[2]. The coefficient of variation (CoV) and the Cramer-Rao lower bounds (CRLB) were calculated for NAA, total Cho (tCho), Cre, Glx and Myo in each voxel. N-way-ANOVA analysis was performed and η^2 values (i.e. proportion of variances) were calculated for each metabolite and multiple factors (repeatibility, scanner, within a volunteer, between volunteers, voxel in the VOI and a random factor considering the noise).
Results: The offset vector of the CSI grid differed 0.55+/-0.13mm between all 120 cases. The difference in angle between the reference from the AC and PC and the transverse plane of the CSI grid was less than 1° anterior-posteriorly, left-right and the cranio-caudally. CSI data from one volunteer in one time point had to be rejected due to artifacts. The CRLB for each voxel in the VOI in the 118 cases ranged from 2-18 % for NAA, from 20-55% for tCho, from 5-28% for Cre, from 20-80% for Myo and from 20-45% for Glx. $\eta^2_{repeatability}$, $\eta^2_{intervolunteer}$ and $\eta^2_{interscanner}$ were less than 1% in all metabolites (except for $\eta^2_{interscanner}$Myo 10%). $\eta^2_{position}$ and η^2_{random} account for the largest contributions in variability (28-68% and 31-60% resp.).
Conclusion: Automated repositioning software proved to be robust. Comparison of CSI data acquisition on the same volunteers using different MR scanners indicates robust quantification using the rapid SENSE-CSI acquisition protocol. However, great care should be taken for metabolite signals with low SNR (e.g.Myo) and in the regions of the chemical shift displacement.
References:
[1] Young et al., Proc. SPIE 2006
[2] Poullet et al. (2007), NMR Biomed

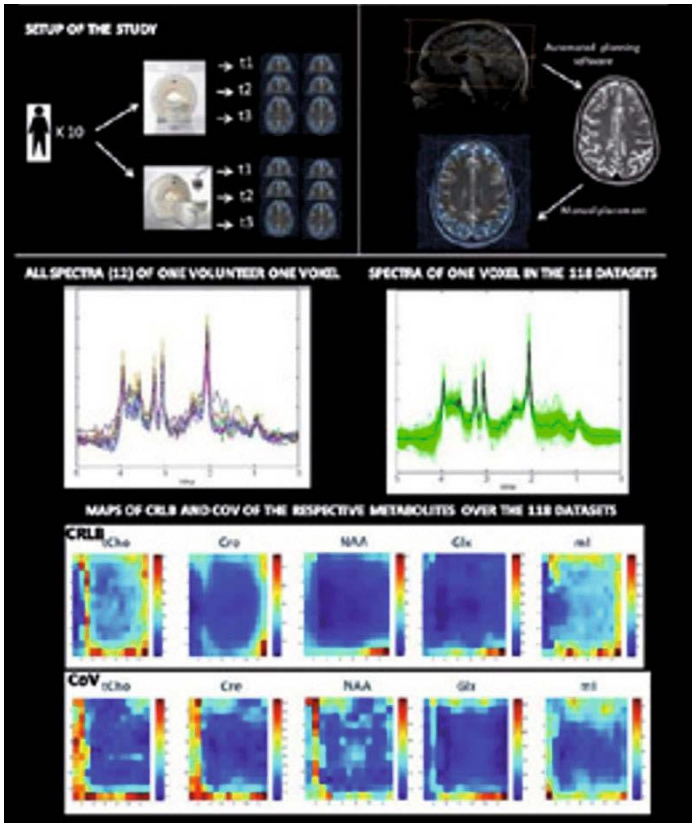

405

Variability of temporal lobe structures in healthy adults- MRI volumetry study

L. Martinkovic[1,2], D. Horinek[2,3], T. Belsan[2,3], P. Marusic[1,4];
[1]Department of neurology, 2nd Faculty of Medicine, Charles University, Prague 5-Motol, Czech Republic, [2]Central Military Hospital, Prague, Czech Republic, [3]1st Faculty of Medicine, Charles university, Prague, Czech Republic, [4]University Hospital Motol, Prague, Czech Republic.

Purpose/Introduction: Temporal lobe and its substructures volumes are used as a research tool in identifying changes in patients with epilepsy, dementia or schizophrenia. Group differences were observed in previous studies, however identification of an atrophy in individual cases is more difficult due to physiological variability of temporal lobe structures. Our aim was to assess temporal lobe and its substructures (temporal pole, hippocampus) volumetry in healthy adults.
Subjects and Methods: 25 right-handed healthy volunteers (13 men, 12 women, median age 44 years) were enrolled into the study. 3-T MRI T1-weighted gradient-echo acquisition with 1.5 mm slice thickness, without gap, was performed. Temporal pole, temporal lobe and intracranial supratentorial volumes bilaterally were measured manually by means of Scanview software in coronal plane, hippocampal volumes in sagittal plane. Normalized data of