TECHNIQUES AND INSTRUMENTATION

Detection of endometrial pathology using saline infusion sonography versus gel instillation sonography: a prospective cohort study

Erika Werbrouck, M.D.,[a] *Joan Veldman, M.D.,*[a] *Jan Luts, Ph.D.,*[b] *Sabine Van Huffel, Ph.D.,*[b] *Dominique Van Schoubroeck, M.D.,*[a] *Dirk Timmerman, M.D., Ph.D.,*[a] *and Thierry Van den Bosch, M.D., Ph.D.*[a]

[a] Department of Obstetrics and Gynecology, University Hospitals, and [b] Department of Electrical Engineering, ESAT-SCD, Katholieke Universiteit Leuven, Leuven, Belgium

Objective: To compare saline infusion sonography (SIS) with gel instillation sonography (GIS) in terms of feasibility and diagnostic accuracy.
Design: Prospective cohort study.
Setting: Leuven University bleeding clinic.
Patient(s): A total of 804 patients: two consecutive cohorts of 402 women undergoing SIS or GIS.
Intervention(s): Vaginal ultrasound (n = 804) followed by SIS (n = 402) or GIS (n = 402); office hysteroscopy in 685 patients, and endometrium sampling in 487 patients; surgery in 274 women: operative hysteroscopy (n = 230) or hysterectomy (n = 44).
Main Outcome Measure(s): Patients' characteristics, technical failure rates, and final diagnosis. Pathology was defined as endometrial hyperplasia, polyp, cancer, or intracavitary myomas.
Result(s): The technical failure rate (difference between proportions and confidence interval) was 5.0% for SIS versus 1.8% for GIS, respectively (3.21; [0.69–5.95]). Failure due to inadequate distension was 1.5% versus 0.3% for SIS and GIS, respectively (1.25; [–0.16–2.99]). Pathology was diagnosed in 180 patients (49%) of the SIS group versus 147 patients of the GIS group (40.2%) (8.88; [1.69–15.95]). The sensitivity was 77.8% and 85.0%, respectively (NS). The negative predictive value was 79.1% for SIS and 88.6% for GIS (9.54; [2.17–16.89]).
Conclusion(s): Gel instillation sonography is a feasible, accurate alternative for SIS in the evaluation of women with abnormal bleeding, and has fewer technical failures. (Fertil Steril® 2010;■:■–■. ©2010 by American Society for Reproductive Medicine.)

Key Words: Endometrium, GIS, SIS, ultrasound

In women with abnormal uterine bleeding, saline infusion sonography (SIS) has been suggested as a simple, noninvasive, accurate technique to evaluate the uterine cavity (1, 2). Stable filling is mandatory to obtain good visualization of the uterine cavity, but reflux of saline through the cervix may result in insufficient distention of the cavity and thus inadequate visualization. The use of higher instillation rates and more expensive balloon catheters to overcome insufficient filling of the cavity may lead to higher intrauterine pressure, causing pain as well as transtubal flow. Although the clinical importance has yet to be demonstrated, transtubal flow may result in seeding of the malignant cells into the abdominal cavity (3). To overcome some problems related to the use of saline, gel instillation sonography (GIS) has been suggested as an alternative to SIS in both premenopausal and postmenopausal women with abnormal uterine bleeding (4, 5). We compared SIS with gel infusion sonography (GIS) in terms of feasibility and diagnostic accuracy.

Received January 22, 2010; revised and accepted April 27, 2010.
E.W. has nothing to disclose. J.V. has nothing to disclose. J.L. has nothing to disclose. S.V.H. has nothing to disclose. D.V.S. has nothing to disclose. D.T. has nothing to disclose. T.V.B. has nothing to disclose.
Supported by Research Council KUL: GOA-MANET; IWT-TBM 070706 (IOTA); and Belgian Federal Science Policy Office: IUAP P6/04 (DYSCO). J.L. supported by an IWT Ph.D. grant.
Reprint requests: Thierry Van den Bosch, M.D., Ph.D., Department of Obstetrics and Gynecology, University Hospitals Leuven, Herestraat 49, 3000 Leuven, Belgium (FAX: 003216344205; E-mail: thiery.van.den.bosch@skynet.be).

MATERIALS AND METHODS

We enrolled 804 patients who had presented at the one-stop Bleeding Clinic of the Department of Obstetrics and Gynecology of the University Hospitals Leuven from October 6, 2004, to December 17, 2008. The two consecutive cohorts of 402 women each consisted of the first 402 women, who underwent SIS, and the next 402, who underwent GIS. Because most women presenting at our Bleeding Clinic have no regular menstrual cycle, ultrasound was performed regardless of the cycle day.

In the first cohort of 402 patients, the ultrasound examination was performed with an Acuson Sequoia 512 (Siemens, Erlangen, Germany) ultrasound machine equipped with an EV-8C4 endovaginal probe. Immediately after baseline transvaginal ultrasound, SIS was performed without local anesthesia. An open-sided speculum was inserted into the vagina, and the cervix was cleaned using

Copyright ©2010 American Society for Reproductive Medicine, Published by Elsevier Inc.

TABLE 1

Patient characteristics.

	SIS	GIS	*P* value
Number	402	402	
Age (y) mean (SD)	50.7 (12.0)	50.2 (11.6)	NS
Nulliparity (%)	12.7	17.4	NS
Premenopausal (%)	53.0	57.2	NS
ET (mm) mean (SD)	9.6 (6.9)	9.1 (6.6)	NS

Notes: ET = endometrial thickness at ultrasound; GIS = gel instillation sonography; NS = not statistically significant; SD = standard deviation; SIS = saline infusion sonography.

Werbrouck. Techniques and instrumentation. Fertil Steril 2010.

FIGURE 1

Comparison of saline infusion sonography (SIS) versus gel instillation sonography (GIS).

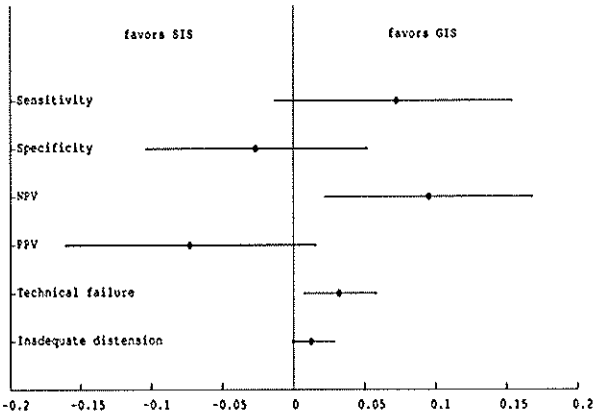

Werbrouck. Techniques and instrumentation. Fertil Steril 2010.

a water solution of cetrimoniumbromide 0.5% and chloorhexidine 0.05%. A neonatal suction catheter 2 mm in diameter was inserted through the cervix, in most cases without the use of a tenaculum and without dilatation of the cervix. The speculum was removed while the catheter was prevented from slipping out by a forceps. The transvaginal ultrasound probe was reinserted, and up to 20 mL of sterile saline was slowly instilled through the neonatal suction catheter until distention of the cavity was sufficient for ultrasound evaluation.

The following 402 consecutive patients underwent a baseline transvaginal ultrasound examination with a GE Kretz Voluson E8 (GE Healthcare, Milwaukee, WI) with a 6-12 MHz 3D endovaginal probe, followed by GIS. The procedure was identical to that of the first cohort, but 3 to 4 mL of gel was instilled instead of saline. To facilitate its instillation through the catheter, the gel was warmed to 37°C to decrease its viscosity. Gel instillation was performed with Instillagel (Farco-Pharma Gmbh, Köln, Germany) or Endosgel (Farco-Pharma Gmbh).

After contrast sonography, office hysteroscopy was performed in 685 patients (367 of the SIS group versus 318 of the GIS group). The endometrium was sampled in 487 patients, and 274 women underwent subsequent surgery. In the SIS group, 131 women underwent operative hysteroscopy and 14 women had a hysterectomy versus 99 and 30, respectively, in the GIS group.

The patients' characteristics, the ultrasound characteristics, the technical failure rates, and the final diagnosis based on endometrial sampling, hysteroscopy, and/or operative hysteroscopy were compared in both groups. The statistical analysis used the Mann–Whitney *U* test as well as interval estimation for the difference between independent proportions (6, 7).

RESULTS

The patients' characteristics are summarized in Table 1. Mean age in the SIS and GIS group was 50.7 years (standard deviation [SD] 12) and 50.2 years (SD 11.6), respectively (not statistically significant). In the SIS group, 12.7% were nulliparous and 53% premenopausal versus 17.4% and 57.2%, respectively, in the GIS group (not statistically significant). Both groups also were similar with respect to the endometrial thickness as measured by transvaginal ultrasound. The technical failure rate (Fig. 1) was 5.0% for SIS versus 1.8% for GIS (difference between proportions 3.21; CI, 0.69–5.95). Failure due to inadequate distension was 1.5% for SIS versus 0.3% for GIS (difference between proportions 1.25; CI, –0.16 to 2.99). Pathology was diagnosed in 180 (49%) patients of the SIS group versus 147 (40.2%) of the GIS group (difference between proportions 8.88; CI, 1.69–15.95) (Fig. 2).The positive likelihood ratio and negative likelihood ratio of contrast sonography for any pathology was 4.04 and 0.28 for SIS, and 3.88 and 0.19 for GIS, respectively (not statistically significant). The sensitivity was 77.8% and 85.0%, respectively (not statistically significant) (Table 2). The negative predictive value was 79.1% for SIS and 88.6% for GIS (difference between proportions 9.54; CI, 2.17–16.89).

DISCUSSION

This study demonstrates the feasibility as well as the diagnostic accuracy of fluid instillation sonography using both saline or gel in the evaluation of women with abnormal vaginal bleeding. Our results support earlier data reported on the SIS (8, 9).Our data show a lower failure rate in the GIS group. This seems at least partly due to the higher viscosity of gel compared with saline, which allows less backflow through the cervix and a better filling of the uterine cavity. By use of gel, less volume was needed to reach a sufficient expansion of the cavity. This may be one of the reasons why gel instillation is associated with less procedure-related pain compared with saline infusion. Promising results with three dimensional (3D) SIS in the evaluation of abnormal vaginal bleeding or uterine abnormalities have been published (10, 11). Because a stable filling of the uterine cavity is mandatory for 3D-volume acquisition, 3D GIS is expected to allow for an equal or better 3D-image quality, without the necessity for a balloon catheter.

The strength of this study is the enrollment of a large number of consecutive patients. Its weakness is the use of consecutive cohorts instead of randomization. Some may assume that the examiner performing the sonohysterography might have experienced a learning curve; however, the examiner in this study had 10 years of experience in the technique at the start of the study, so a bias due to a learning curve favoring the second cohort is therefore less likely (12). A different ultrasound machine was used in the second part of our study. Although we did not have the impression that the image quality was different between

FIGURE 2

Final histologic diagnosis, saline infusion sonography (SIS) versus gel instillation sonography (GIS). atrophy = endometrial atrophy; hyperpl. = endometrial hyperplasia; myoma = intracavitary myoma; cancer = endometrial cancer; prolif. = proliferative endometrium; secret = secretory endometrium; polyp = endometrial polyp.

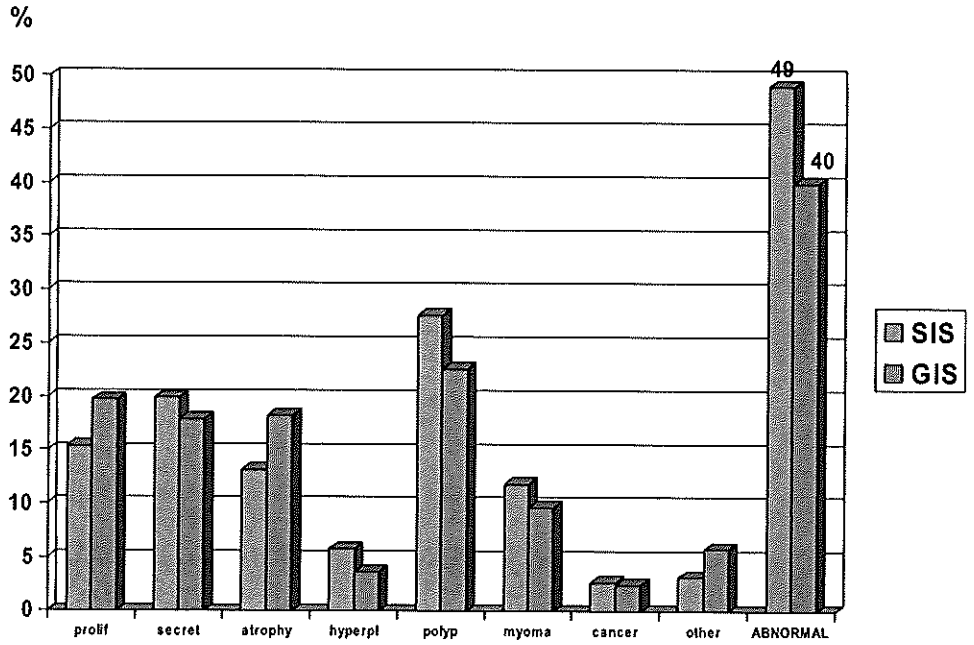

Werbrouck. Techniques and instrumentation. Fertil Steril 2010.

both machines, we cannot exclude that this may have influenced our results.

Different gel-types are available. The difference between Endosgel and Instillagel is that the latter contains lidocaine. In both chlorhexidine is added. One randomized trial looked at the effect of adding lidocaine to the gel used for GIS and could not demonstrate any difference in patients' experienced pain (13).

Although, in our series, we did not notice any allergic reactions, very rare cases of allergic reaction to lidocaine or chlorhexidine have been reported. All patients should therefore be asked for known allergies before proceeding with GIS (14, 15).

Concerns may be raised about upper genital tract infection secondary to the insertion of a catheter and the instillation of fluid. There are few data published on infection risk after sonohysterography, and endometritis is found to be a rare complication (16, 17). According to a Cochrane analysis, there is no evidence to support or to discourage the use of antibiotics to prevent infections during any transcervical intrauterine procedure. Therefore, we believe that prophylactic antibiotics should be reserved to high-risk patients (18). Gels with chlorhexidine could have an advantage (19, 20), but to the best of our knowledge, this has yet to be studied. Embryotoxicity is another unsolved issue, so we do not use GIS in the luteal phase of the cycle.

Fluid instillation in the cavity may facilitate dissemination of malignant cells through the fallopian tubes into the peritoneal cavity. Higher positive peritoneal cytology results after hysteroscopy have been reported (21–23). Although the volume and the pressure of saline solution required for adequate expansion of the uterine cavity are notably lower in SIS compared with hysteroscopy, dissemination of malignant cells into the peritoneal cavity during SIS has been seen (3, 24, 25). Whether isolated positive cytology alters the prognosis of those patients remains controversial. Endometrial cancer suspected on baseline transvaginal ultrasound is a relative contraindication for fluid instillation. Due to its higher viscosity and because of the low instillation volume, the risk of flushing malignant cells into the abdominal cavity is, at least theoretically, less with instillation of gel compared to saline.

A potential pitfall of using gel is the misdiagnosis of intrauterine blood clots for a small polyp or myoma. With saline, a intrauterine clot can be flushed away, allowing for a better evaluation of the endometrium. Dynamic assessment of the endometrium should

TABLE 2

Diagnostic accuracy for intracavitary pathology at saline infusion sonography (SIS) and gel instillation sonography (GIS).

	SIS	GIS	*P* value (CI)
Sensitivity (%)	77.8	85.0	NS
Specificity (%)	80.7	78.1	NS
NPV (%)	79.1	88.6	.095 (0.022–0.17)
PPV (%)	79.5	72.3	NS
LR+	4.03	3.90	NS
LR–	0.28	0.19	NS

Notes: LR+ = positive likelihood ratio; LR– = negative likelihood ratio; NPV = negative predictive value; NS = not statistically significant; PPV = positive predictive value.

Werbrouck. Techniques and instrumentation. Fertil Steril 2010.

overcome this problem. By gently pushing onto the cervix with the endovaginal probe while moving the fundus of the uterus by abdominal palpation, intracavitary contents may be mobilized: blood clots tend to move in the cavity, myomas or polyps do not. Slowly pulling on the catheter while instilling can also help in the differential diagnosis.

We conclude that both SIS and GIS are feasible and accurate techniques to evaluate the uterine cavity in patients with abnormal uterine bleeding. Gel has some advantages over saline: stable filling of the uterine cavity, no need for balloon catheters, improved patient comfort, and, theoretically, a lower risk for intraperitoneal dissemination of malignant cells. Therefore, we recommend the use GIS instead of SIS.

REFERENCES

1. De Kroon CD, de Bock GH, Dieben SWM, Jansen FW. Saline contrast hysterosonography in abnormal uterine bleeding: a systematic review and meta-analysis. BJOG 2003;110:938–47.
2. De Kroon C, Jansen FW, Louwé LA, Dieben SWM, van Houwelingen HC, Trimbos JB. Technology assessment of saline contrast hysterosonography. Am J Obstet Gynecol 2003;188:945–9.
3. Dessole S, Rubattu G, Farina M, Capobianco G, Cherchi PL, Tanda T, et al. Risks and usefulness of sonohysterography in patients with endometrial carcinoma. Am J Obstet Gynecol 2005;194:362–8.
4. Exalto N, Stappers C, Emanuel MH. Gel instillation sonohysterography: first experience with a new technique. Fertil Steril 2007;87:152–5.
5. Van den Bosch T, Betsas G, Van Schoubroeck D, Daemen A, Vandenbroucke V, Cornelis A, et al. Gel infusion sonography (GIS) in the evaluation of the uterine cavity. Ultrasound Obstet Gynecol 2009;34: 711–4.
6. Hollander M, Wolfe DA. Nonparametric statistical methods. New York: John Wiley and Sons, 1973.
7. Newcombe RG. Interval estimation for the difference between independent proportions: comparison of eleven methods. Stat Med 1998;17:873–90.
8. Dijkhuizen EPHL, De Vries LD, Mol BWJ, Brölmann HA, Peters HM, Moret E, et al. Comparison of transvaginal ultrasonography and saline infusion sonography for the detection of intracavitary abnormalities in premenopausal women. Ultrasound Obstet Gynecol 2000;15:372–6.
9. Goldstein SR. Use of ultrasonohysterography for triage of perimenopausal patients with unexplained uterine bleeding. Am J Obstet Gynecol 1994;170: 565–70.
10. De Kroon CD, Louwé LA, Trimbos JB, Jansen FW. The clinical value of 3-dimensional saline infusion sonography in addition to 2-dimensional saline infusion sonography in women with abnormal uterine bleeding. J Ultrasound Med 2004;23: 1433–40.
11. Salim R, Lee C, Davies A, Jolaoso B, Ofuasa E, Jurkovic D. A comparative study of three-dimensional saline infusion sonohysterography and diagnostic hysteroscopy for the classification of submucous fibroids. Hum Reprod 2005;20: 253–7.
12. Vandendael A, Debois P, Van den Bosch T. Sonohysterography in the detection of endometrial pathology. S Afr Med J 1995;85:1197.
13. Van den Bosch T, Domali E, Vandenbroucke V, Deprest J, Timmerman D. The addition of lidocaine to the gel used for gel infusion sonography (GIS): effect on pain perception during GIS and subsequent hysteroscopy and endometrial sampling [abstract]. Ultrasound Obstet Gynecol 2008;32:257.
14. Parkes AW, Haper N, Herwadkar A, Pumphrey R. Anaphylaxis to the chlorhexidine component of Instillagel: a case series. Br J Anaesth 2009;102: 65–8.
15. Van Zuuren EJ, Boer F, Lai a Fat EJ, Terreehorst I. Anaphylactic reactions to chloorhexidine during urinary catheterisation [in Dutch]. Ned Tijdschr Geneeskd 2007;151:2531–4.
16. Dubinsky TJ, Parvey HR, Gormaz G, Curtis M, Maklad N. Transvaginal hysterosonography: comparison with biopsy in the evaluation of postmenopausal bleeding. J Ultrasound Med 1995;14:887–93.
17. Bonnamy L, Marret H, Perrotin F, Body G, Berger C, Lansac J. Sonohysterography: a prospective survey of results and complications in 81 patients. Eur J Obstet Gynaecol Reprod Biol 2002;102:42–7.
18. Thinkhamrop J, Laopaiboon M, Lumbiganon P. Prophylactic antibiotics for transcervical intrauterine procedures. Cochrane Database Sys Rev 2007;18:CD005637.
19. Faul-Bugzame P. Efficacy of Instillagel against methicillin-resistant strains of staphylococcus aureus in urinary bladder catheterization. Urologia 2007;6: 14–6.
20. Scholtmeijer RJ, Dzoljic-Danilovic G. Disinfecting effect of a disposable lubricant during cystoscopy. Child Nephrol Urol 1990;10:22–5.
21. Revel A, Tsafrir A, Anteby SO, Shushan A. Does hysteroscopy produce intraperitoneal spread of endometrial cancer cells? Obstet Gynecol Surv 2004;59:280–4.
22. Yazbeck C, Dhainaut C, Batallan A, Benifla JL, Thoury A, Madelenat P. Diagnostic hysteroscopy and risk of peritoneal dissemination of tumor cells. Gynecol Obstet Fertil 2005;33:247–52.
23. Takac I, Zegura B. Office hysteroscopy and the risk of microscopic extrauterine spread in endometrial cancer. Gynecol Oncol 2007;107:94–8.
24. Alcazar JL, Errasti T, Zornoza A. Saline infusion sonohysterography in endometrial cancer: assessment of malignant cells dissemination risk. Acta Obstet Gynecol Scand 2000;79:321–2.
25. Berry E, Lindheim SR, Connor JP, Hartenbach EM, Schink JC, Harter J, et al. Sonohysterography and endometrial cancer: incidence and functional viability of disseminated malignant cells. Am J Obstet Gynecol 2008;199:240.e1–8.