COMPARISON OF DIFFUSION KURTOSIS IMAGING, DYNAMIC SUSCEPTIBILITY WEIGHTED IMAGING AND SHORT ECHO TIME CHEMICAL SHIFT IMAGING FOR GRADING GLIOMAS

Sofie Van Cauter[1], Diana M. Sima[2], Anca R. Croitor Sava[2], Jelle Veraart[3], Stefan Sunaert[1,4], Sabine Van Huffel[2], and Uwe Himmelreich[5]

[1]Radiology, University Hospitals of Leuven, Leuven, Vlaams-Brabant, Belgium, [2]ESAT-PSI, Department of Electrical Engineering, Catholic University of Leuven, Heverlee, Vlaams-Brabant, Belgium, [3]Vision Lab, Department of Physics, University of Antwerp, Antwerp, Antwerp, Belgium, [4]Translational MRI, University Hospitals of Leuven, Leuven, Vlaams-Brabant, Belgium, [5]Biomedical NMR Unit/Molecular Small Animal Imaging Center, Department of Medical Diagnostic Sciences, Catholic University Leuven, Leuven, Vlaams-Brabant, Belgium

Target audience: Neuroradiologists and MR scientists with an interest in advanced MR techniques and their practical implementation to address problems encountered in routine clinical practice.

Purpose: Adequate grading of gliomas presents many difficulties in clinical practice but is of capital importance because treatment regimens and prognosis depend on the malignancy grade. Currently, a biopsy is warranted in order to obtain a definitive diagnosis. An imaging-based method for determining glioma grade is appealing due to its non-invasiveness. Several studies, using advanced MR techniques to grade gliomas have been published, although most of the reported results were demonstrated on a group level. In order to find acceptance in clinical practice, prospective grading of gliomas should be performed on an individual patient level with sufficient accuracy. Moreover, combining different modalities has the potential to increase diagnostic accuracy, as the different advanced MR techniques yield complementary information. In this study, it was our aim to assess the separate diagnostic performances of diffusion kurtosis imaging (DKI) [1], dynamic susceptibility-weighted MR imaging (DSC-MRI) and short echo time chemical shift imaging (CSI) for grading gliomas, and to examine if a multimodal approach could be used to improve these results.

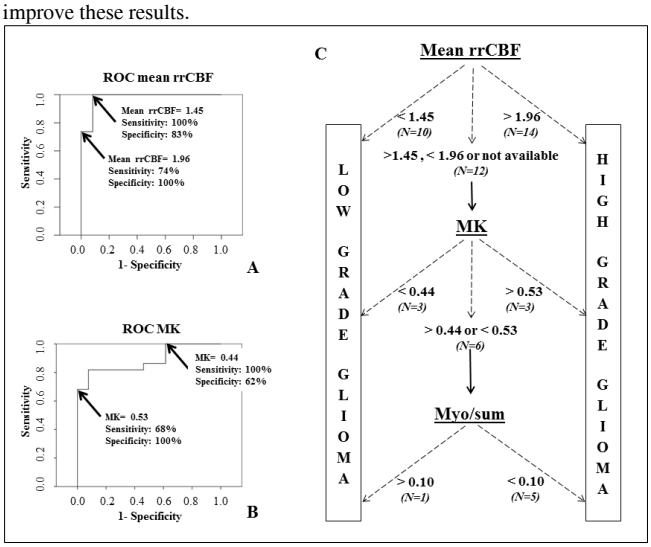

Fig1:
A, ROC curve indicates the sensitivities and specificities of mean rrCBF-based differentiation between low and high grade gliomas.
B, ROC curve indicates the sensitivities and specificities of MK-based differentiation between low and high grade gliomas. The two indicated points show the range where misclassifications can occur in this specific study population.
C, Decision tree to distinguish low from high grade glioma in our study population based on the ranges of possible misclassification of mean rrCBF and MK determined in A and B respectively and the optimal cut off value of Myo/sum. The number of patients belonging to each decision step

Material and methods: Thirty-five patients with cerebral gliomas (12F/23M; age range: 22-78 years, median age: 55 years) underwent DKI, DSC and CSI on a 3T MR scanner, implementing previous published protocols [2-4]. Diffusion parameters - mean diffusivity (MD), fractional anisotropy (FA), mean kurtosis (MK) -, perfusion parameters – mean relative regional cerebral blood volume (mean rrCBV), mean relative regional cerebral blood flow (mean rrCBF), mean transit time (MTT) and relative decrease ratio (rDR), – and twelve CSI metabolite ratios- were compared between 22 high grade gliomas and 14 low grade gliomas (Mann-Whitney-U, $p<0.05$, Bonferroni correction). The classification accuracy, sensitivity, specificity, negative predictive value and positive predictive value were determined with a linear discriminant analysis. To combine the DKI, DSC-MRI and CSI information, we propose a decision-tree rule. The receiver operating characteristic (ROC) curve was used to determine for each statistically significant parameter a low-confidence interval. We made a first attempt to join the discriminatory capabilities of each modality to present a decision tree using the parameters with the highest combined added value. If at any of the decision-tree levels the parameter value is outside the previously mentioned low-confidence interval, we can accurately predict the tumor grade and a further level is not needed.

Results: MK, MD, mean rrCBV, mean rrCBF, rDR, Lips/tCho, Lips/Cre, Myo/sum and Cre/sum showed statistically significant differences among tumor grades, with mean rrCBF as the best discriminative parameter of the perfusion parameters and MK as the best discriminative parameter of the diffusion parameters. The classification accuracy, sensitivity, specificity, negative predictive value and positive predictive value of DKI, DSC and CSI datasets for differentiating low from high grade glioma are shown in Table 1. When considering the statistical significant DSC parameters, the performance reached 83%. Based on the DKI and CSI data the accuracy is overall lower. For the current dataset, the combination of mean rrCBF, MK and Myo/sum to grade gliomas could even show a diagnostic accuracy of 100%. Based on the ROC analysis, the mean rrCBF low-confidence interval for the current dataset was 1.45 -1.96. For the cases where the mean rrCBF value was situated in this range (12 cases, 33%), MK was considered. The low-confidence interval for MK was 0.44 to 0.53. From these twelve cases, six MK values were in this range. In these remaining six datasets, Myo/sum was able to distinguish low from high grade gliomas in all cases based on the optimal cutoff value (0.10). Based on this decision-tree rule all case within our data were correctly graded (Fig 1). The combination of a high mean rrCBF, a high MK and low Myo/sum was diagnostic for high grade glioma (Fig 2). Of course, the optimal combinations and cut-offs of imaging parameters will need to be examined in a larger dataset.

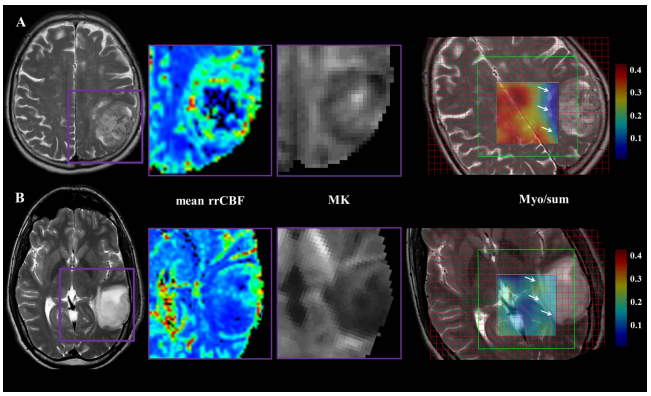

Detection value	*DKI* MK and MD	*DSC* Mean rrCBV, Mean rrCBF and rDR	*CSI* Lips/tCho, Myo/sum, Cre/sum and Lips/Cre
Diagn. acc.	77%	83%	75%
Sensitivity	68%	78%	72%
Specificity	92%	91%	78%
PPV	93%	93%	81%
NPV	63%	73%	68%

Table 1:Linear discriminant analysis performance in the separation between high and low grade gliomas. The mean accuracy, sensitivity, specificity, negative predictive value and positive predictive value over 100 runs are reported.

Fig 2:
T2-weighted image, mean rrCBF, MD and Myo/sum maps of a 71-year old female patient with a glioblastoma multiforme in the left parietal lobe (panel A) and a 35-year old male patient with a grade II pilocytic astrocytoma in the left temporal lobe.

Conclusion: The most accurate parameters for determination of glioma grade were MK and mean rrCBF. However, a combination between calculated parameters could still provide a better differentiation between high- and low-grade glioma in this data set; this should be further explored in a larger study population.

References: [1] Fieremens et al, *Neuorimage* 2011 **[2]** Poot et al, *IEEE Trans Med Imaging* 2010 **[3]** Van Cauter et al, *Neuroradiology* 2011 **[4]** Van Cauter et al, *JMRI* 2012